A0135

Novel automated processing techniques of fluorescein angiography (FA) images in patients with Uveitis

National Eye Institute
Medical Research Scholars Program

Natasha Kesav[1], Qixin Yang[2], Wolfgang Losert[2], Jongwoo Kim[3], Stefan Jaeger[3], H. Nida Sen[1]

[1]Laboratory of Immunology, National Eye Institute (NEI), Bethesda, MD, [2]Department of Physics, University of Maryland, College Park, MD, [3]Lister Hill National Center of Biomedical Communications, U.S. National Library of Medicine

Northeast Ohio Medical University — Education · Service · Research — 1973

ABSTRACT

- Fluorescein angiography (FA) is a diagnostic imaging modality to visualize abnormalities in retinal and choroidal circulation such as vascular leakage.
- There is a need of objective quantification and detection of vascular pathology in uveitis.
- **We demonstrate the potential of two novel automated processing techniques to detect leakage in FA images.**

METHODS

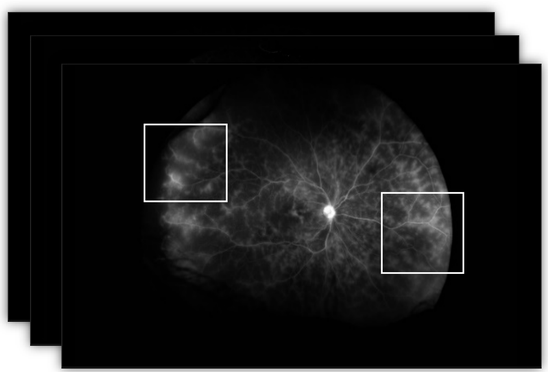

- Images used in this study belonged to patients enrolled in the Uveitis/Intraocular Inflammatory Biobank (iBank) protocol at the NEI who underwent FA using the Optos 200Tx (Optos plc, Dunfermline, United Kingdom)
- Individual early and mid-phase angiographic images were selected if vascular leakage was identified by expert readers.
- Patient images were excluded in the cases of poor image quality, media opacity and severe artifacts obscuring view.
- Angiographic Images were retrospectively downloaded, removed of patient identifying information, and exported to analysis software.

APPROACH 1 || APPROACH 2

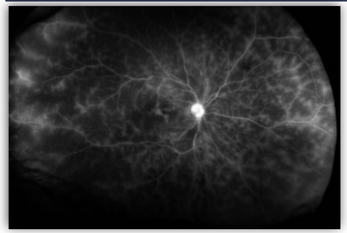

1. Pre-processing

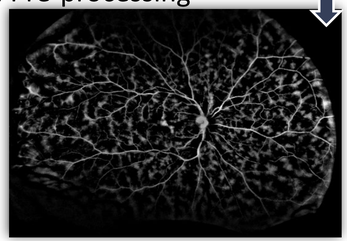

2. Adaptive binarization

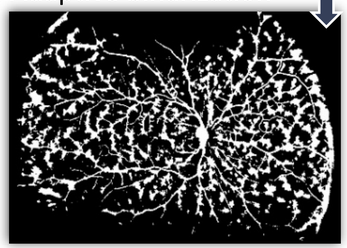

3. Detection of vasculature



4. Vascular tree subtraction

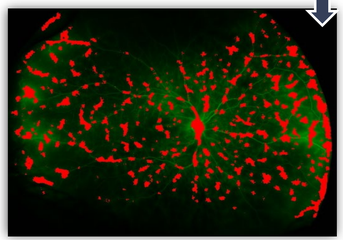

1. Rotating Laplacian of Gaussian convolution in various angles

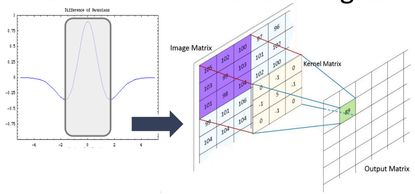

2. Convolve filters to max project onto one image and binarize

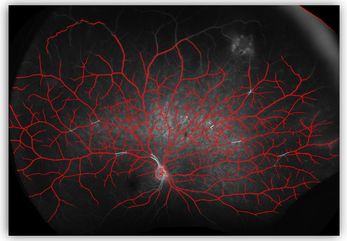

3. Detection of leakage using local pixel intensities + segmentation with Kmeans clustering

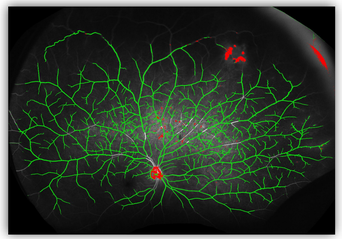

Further applications: Curvature calculation and junction detection

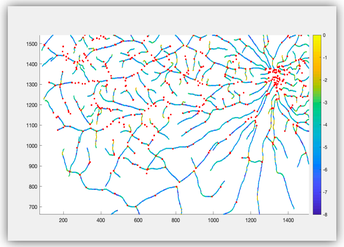

RESULTS

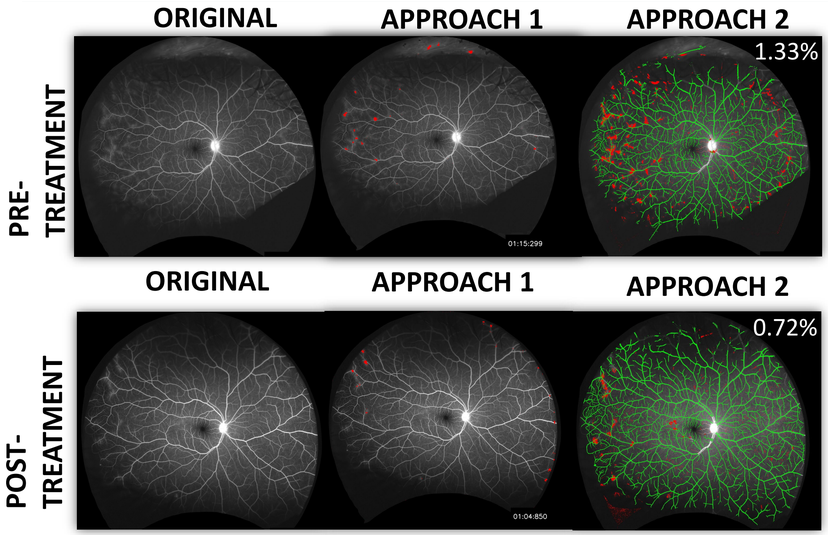

*Application of **approach 1 and approach 2** before and after oral corticosteroids in a patient with mild vasculature leakage. Approach 2 demonstrates quantifiable improvement in leakage after treatment.*

LIMITATIONS & FUTURE DIRECTION

Limitations:

- Different FOVs in FA videos in the same clinical practice
- Distortion of images due to eye movement and blinking
- Interframe motion cannot be modeled as rigid
- Uveitis: vitreous haze could confound visible media

Future Directions:

- Refinement of algorithms + deep learning integration
- Reproducibility and repeatability across multicenter trials
- Explore skeleton structure as predictor/marker of disease

CONCLUSION

Our methods of FA image processing provides two novel algorithmic approaches to identifying leakage in patients with uveitis. Further refinement is warranted to apply to real-world patient care.

Contact: Natasha.Kesav@nih.gov.

Support: Intramural Research Program of the National Institutes of Health (NIH). **Disclosure and Commercial Relationships:** None